

*Prikazi bolesnika/
Case reports*

CERUMINOUS MIDDLE EAR ADENOMA

CERUMINOZNI ADENOM SREDNJEG UVA

Milan Erdoglija¹, Jelena Sotirovic¹, Ljubica Zivic²,
Biserka Vukomanovic³

Correspondence to:

dr **Milan Erdoglija**,
ORL Klinika VMA
Ul. Crnotravska 17
11000 Beograd
Mob. tel. 0658316009
E-mail: milan.erdoglija@gmail.com

¹ ENT Clinic, Military Medical Academy, Belgrade

² ENT Clinic, Clinical Center, Kragujevac

³ Institute of Pathology, Military Medical Academy, Belgrade

Key words

ceruminous adenoma, middle ear,
neoplasm, biopsy

Ključne reči

ceruminozni adenom, srednje uvo,
neoplazma, biopsija

Abstract

Ceruminous middle ear adenoma is a benign neoplasm with good clinical behavior. The main clinical feature of the ceruminous middle ear adenoma is painless chronic purulent otitis leading to deterioration of hearing. The diagnosis of ceruminous adenoma of the middle ear is made clinically using anamnesis, otoscopy examination, audiologic and vestibular assessment and radiological findings. The definitive diagnosis is made on histological finding. Surgical treatment with complete neoplasm excision and regular follow-up provide excellent long-term result without recurrence of the neoplasm.

INTRODUCTION

Ceruminous adenoma is a rare benign neoplasm of the external auditory canal and even more rarely neoplasm of the middle ear, with good clinical prognosis (1). Ceruminous adenoma mainly consists of ceruminous glandular cells (modified apocrine sweat glands) (4). Ceruminous glands are located in the cartilaginous part of the external auditory canal and the tumor usually occurs in the outer third of the ear canal. Clinically ceruminous adenoma seems as a polypous like tumefaction in an external auditory canal with greater or lesser ear obstruction and consequent otorrhea or diffuse otitis of the external auditory canal. A biopsy of the tumor is essential for the diagnosis of malignant neoplasms and choice of treatment protocols. Ceruminous pigment detection, CK7, p63 and S-100 can help distinguishing ceruminous adenomas from other neoplasm in this region (6). Complete ceruminous adenoma surgical excision leads to excellent long-term results.

Ceruminous adenoma of the middle ear has a different clinical picture of ceruminous adenoma of external ear canal. There are not ceruminous glands located in the middle ear. Middle-ear ceruminous adenomas are rare benign neoplasms arising from the epithelium of the middle ear (5,11). This is unclear etiology of ceruminous adenoma genesis in the middle ear. The ectopic origin in the modified apocrine ceruminous glands, the specific localization, the clinical features and the extremely rare occurrence of the ceruminoma makes this tumor a unique neoplastic entity (7). Ceruminous middle ear adenoma symptoms are painless,

smelly, chronic otorrhea, unilateral hearing impairment with or without dizziness, while clinical signs of a perforated eardrum with grits and debris in the pulp chamber timpani more point to chronic purulent otitis with polypous or cholesteatoma, then to the occurrence of neoplasm (2,11). Diagnosis involves anamnesis, otoscopy examination, pure tone audiometry, vestibular assessment and X-ray mastoid Schuller view. MSCT temporal bone is important for determining the boundaries of neoplasms. Surgical treatment involves some types of the tympanoplasty with complete neoplasm excision. Ex tempore biopsy determines surgery radicalism, since preoperative biopsy of the tumor in the outpatient office is hard to perform (3). Histological finding of the excised tumor was credited with the definitive diagnosis of the ceruminous adenoma. Postoperative monitoring of patients with operated ceruminous adenoma is necessary in a longer time interval because of the possibility of recurrence of the tumor.

CASE REPORT

A 59-year-old male with chronic suppurative otitis media on his left ear was admitted to ENT Clinic MMA for surgery. Mastoidectomy on his left ear had been performed 37 years ago following chronic mastoiditis. After the first operation, he was satisfied with his hearing and with dry operated ear for many years. During the past three years he has been feeling tinnitus, decrease of his hearing on his left ear and leaking of his left ear, three or four times a year. Also he has been suffering from positional vertigo and cervical spondylosis.

On the other hand, he was in good physical condition, without any systematic diseases. He was not in a habit to smoke or drink alcohol. Otoscopy examination showed central perforation on his left eardrum with some soft tissue visible in the tympanic cavity. As the clinical picture suggested a suspected cholesteatoma or granulation like tissue, radiological imaging was performed. The MSCT scan of temporal bones showed signal enhancement in the areas of the old mastoid cavity and some rare mastoid cells in the tympanic cavity, too (fig.1). Pure-tone audiometry number 2051/11 showed mild mixed hearing loss in his left ear (fig.2) and slight sensorineural hearing loss in his right ear in high frequencies. Functional aspects of body balance were normal. Dix Hallpike test and Daroff test were negative. Postrotatory responses were normal and equal on both ears. Blood tests showed normal results. After all preoperational examinations, we performed surgery under general anesthesia. Intraoperative view was the following: Granulation like tissue was found in the mastoid cavity and in the upper part of the tympanic cavity. Ossicular chain was disrupted and we performed both ossiculoplasty and graft myringoplasty. However, the suspected cholesteatoma could not be confirmed intraoperatively. Histological finding revealed a ceruminous gland adenoma (fig.3). Immunohistochemical

expression of p63 protein was positive in the ceruminous adenoma. Follow-up hasn't shown any improvement in hearing in a two-year period after the operation. The patient still feels positional vertigo and tinnitus on his left ear. After the otoscopy examination we can notice that the eardrums on his both ears are normal, without any episodes of leaking. Control pure-tone audiometry showed the same level of hearing loss.

DISCUSSION

Ceruminous middle ear adenoma is a rare phenomenon and should be distinguished from middle ear adenomas, pleomorph ceruminous gland adenomas, syringocystadenoma, ceruminous gland adenocarcinomas and cylindromas of the ceruminous glands (8,9,10). Owing to a high recurrence rate, complete surgical removal is necessary.

Differential diagnosis: Despite its rare occurrence, a ceruminous gland adenoma must be taken into consideration in the differential diagnosis of individual cholesteatoma cases (5). Very important thing is to avoid misdiagnosis of some malignant tumor. Every suspicion of malignant tumor should be proceeded by biopsy or „ex tempore” histological

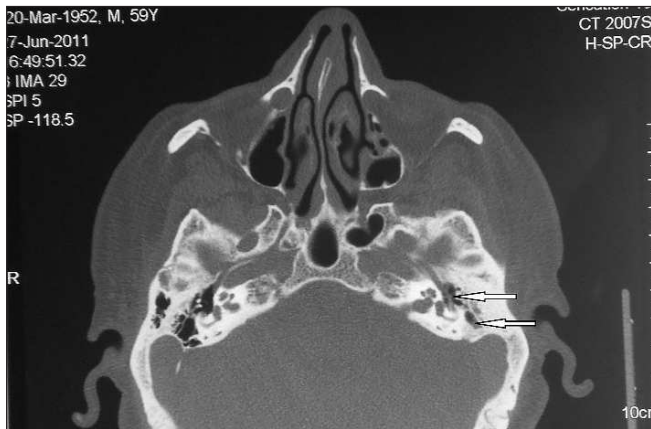


Figure 1. MSCT scan of temporal bones showed soft pathological tissue in the tympanic cavity (arrows pointed to the ceruminoma)

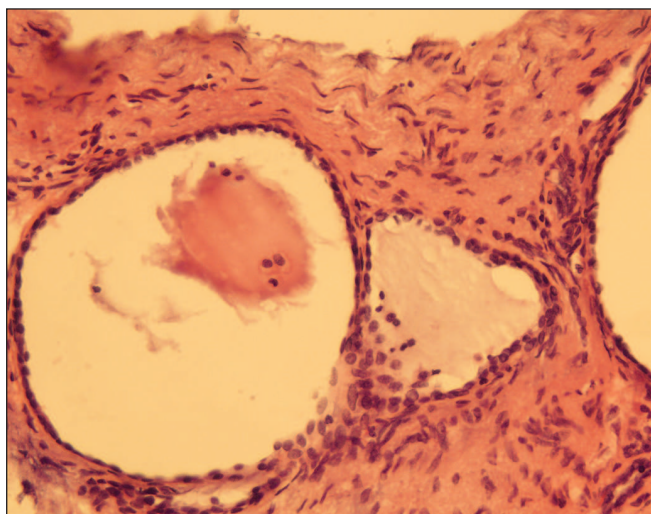


Figure 2. Pure-tone audiometry number showed mild mixed hearing loss in his left ear

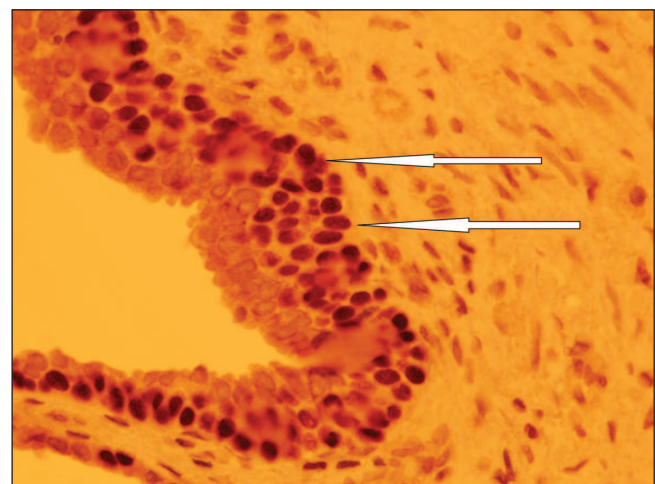
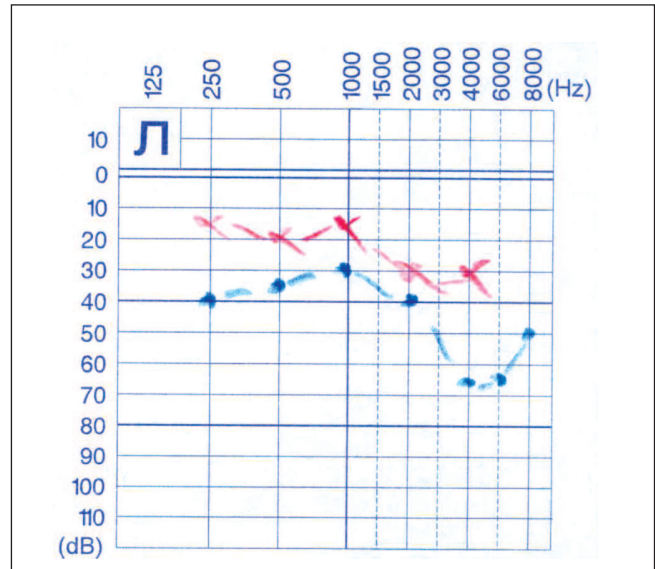


Figure 3. Histological finding of ceruminous middle ear adenoma-round glands consisted of two cells lines – epithelial luminal cells and basal, myoepithelial, albuminal cells. The basal cells were highlighted with p63 (arrows showed basal cells).

findings during the operation. Ceruminous adenocarcinoma is characterized by more infiltrative pattern, perineural invasion, irregular gland formation and pleomorphism with prominent nucleoli, increased mitotic figures including atypical mitotic figures and tumor necrosis. Usually no ceruminous granules are noted (2).

CONCLUSION

The diagnosis of ceruminous adenoma tumor in the middle ear is made after precise histological finding. Surgery is still the only therapeutic treatment for ceruminous adenoma tumor. Ceruminous adenoma should be radically excised with adequate margins of normal tissues. MSCT scan helps to determine margins of tumor extendings. Complete surgical excision results in an excellent long-term clinical outcome.

Sažetak

Ceruminozni adenom srednjeg uva je benigna neoplazma sa dobrom kliničkom slikom. Glavna klinička karakteristika ceruminoznog adenoma srednjeg uva je bezbolna hronična gnojna upala srednjeg uva koja dovodi do deteriozacije sluha. Dijagnostiku ceruminoznog adenoma srednjeg uva obuhvata: anemneza, otomikroskopiranje, audiovestibulometrija i radiološke pretrage. Definitivna dijagnoza se postavlja uz pomoć patohistološkog nalaza. Hirurško lečenje sa potpunim ekscidiranjem neoplazme i redovno postoperativno praćenje obezbeđuju odličan i dugoročan rezultat bez recidiva bolesti.

REFERENCES

1. Mills RG, Douglas-Jones T, Williams RG. Ceruminoma – a defunct diagnosis. *J Laryngol Otol.* 1995;109(3):180-8
2. Lassaletta L, Patron M, Oloriz J, Perez R, Gavilan J. Avoiding misdiagnosis in ceruminous gland tumors. *Auris Nasus Larynx.* 2003 Aug;30(3):287-90
3. Mansour P, George MK, Pahor AL. Ceruminous gland tumors: a reappraisal. *J Laryngol Otol.* 1992 Aug;106(8):727-32
4. Namysowski G, Scierski W, Misiołek M, Czecior E, Lange D. Ceruminous gland adenoma of the external auditory canal: a case report. *Otolaryngol Pol.* 2003;57(5):755-9.
5. Teschner M, Buhr T, Donnerstag F, Lenarz T, Majdani O. Expansion of an ceruminous adenoma into the middle ear. *Laryngorhinotologie.* 2006 Jun;85(6):444-7.
6. Thompson LD, Nelson BL, Barnes EL. Ceruminous adenomas: a clinicopathologic study of 41 cases with a review of the literature. *Am J Surg Pathol.* 2004 Mar;28(3):308-18.
7. Schenk P, Handisurya A, Steurer M. Ultrastructural morphology of a middle ear ceruminoma. *ORL J Otorhinolaryngol Relat Spec.* 2002 Sep-Oct;64(5):358-63.
8. Moss R, Labay G, Mehta N. Ceruminoma revisited. *Am J Otol.* 1987 Nov;8(6):485-8.
9. Kuczkowski J, Izycka-Swieszewska E, Plichta Ł, Cieszyńska J. Combined tumor of ceruminous gland origin in the external auditory canal—a histopathological and immunohistochemical study. *Otolaryngol Pol.* 2010 Nov-Dec;64(6):385-7. doi: 10.1016/S0030-6657(10)70592-8.
10. Markou K, Karasmanis I, Vlachtsis K, Petridis D, Nikolaou A, Vital V. Primary pleomorphic adenoma of the external ear canal. Report of a case and literature review. *Am J Otolaryngol.* 2008 Mar-Apr;29(2):142-6. doi: 10.1016/j.amjoto.2007.04.005.
11. Orendorz-Fraczkowska K, Jaworska M, Gawron W, Badowski R. Middle-ear ceruminous adenoma as a rare cause of hearing loss and vertigo: case reports. *Auris Nasus Larynx.* 2005 Dec;32(4):393-7. Epub 2005 Sep 27.