

*Prikazi bolesnika/
Case report*

THE REPORT OF UNTREATED
PSORIATIC ARTHRITIS

PRIKAZ BOLESNICE SA NELEČENIM
PSORIJAZNIM ARTRITISOM

Correspondence to:

Aleksandar Jokić, MD, MSc
Specialized Hospital for Rehabilitation
Banja Koviljača Spa, Serbia
Town: Banja Koviljača, Post code 15316,
zip code / + 381
State: Serbia
Mob. Phone / +381 64 873 1317
Home / + 381 15 882-301
E-mail: jokic71@gmail.com

Aleksandar Jokić¹, **Zoran Grujić**¹, **Nikola Sremčević**¹,
Nada Pilipović², **Vesna Ristanović**³

¹Specialized Hospital for Rehabilitation, Banja Koviljača, Serbia

²Institute for Rheumatology, Belgrade, Serbia

³General Hospital, Užice, Serbia

Key words

Psoriasis, arthritis, rehabilitation

Ključne reči

Psorijaza, artritis, rehabilitacija

Abstract

OBJECTIVE: Report of female patient with untreated psoriatic arthropathy.

METHODS: Female patient, M.M. 38 years. She has had psoriasis since the age of 18 (1984). From 1995 to 1998, deformities with contractures in right then left foot, hands, elbows and knees were made. She has been unable to move since November 26, 1998. The treatment with modifying medicines (MTX 10 mg) and glucocorticosteroids (Pronison 5 mg) was started in 2002, when she already had pronounced flexion contractures in all joints of arms and legs. At first rehabilitation in 2004, patient was in a wheelchair, dependant in transfer with definite contractures in all joints of arms and legs, fingers in ulna deviation, performs only tweezers' catch. General hypotrophy of muscles with muscle strength reduction. Psoriatic changes are present on nails, elbow skin, right knee, thoraco-lumbar spine and head. Her rehabilitation plan was as following: kinesitherapy, paraffin, magnetic, photo, hydro and Horizontal, six days per week, once daily, for 30 days. No one in her family has had either psoriasis or arthritis.

RESULTS: Patient was put in vertical position for walk in parallel bars with additional knee stabilization, contractures of hips and knees were reduced, muscle strength in legs was improved, pain intensity in joints was reduced, psoriatic changes on skin are less pronounced, the patient has been motivated for continuing rehabilitation.

CONCLUSION: Untreated disease due to passive attitude of the patient led to definite anatomically deformities, severe functional damages of joints and immediate invalidity.

INTRODUCTION

Psoriatic arthritis is a chronic disease characterized by inflammation of the skin (psoriasis) and joints (arthritis). Psoriasis is a common skin condition affecting 2% of the Caucasian population in the United States. It features patchy, raised, red areas of skin inflammation with scaling. Psoriasis often affects the tips of the elbows and knees, the scalp, the navel, and around the genital areas or anus. Approximately 10% of patients who have psoriasis also develop an associated inflammation of their joints. Patients who have inflammatory arthritis and psoriasis are diagnosed as having psoriatic arthritis.

The onset of psoriatic arthritis generally occurs in the fourth and fifth decades of life. Males and females are affected equally. The skin disease (psoriasis) and the joint disease (arthritis) often appear separately. In fact, the skin disease precedes the arthritis in nearly 80% of patients. The

arthritis may precede the psoriasis in up to 15% of patients. In some patients, the diagnosis of psoriatic arthritis can be difficult if the arthritis precedes psoriasis by many years. In fact, some patients have had arthritis for over 20 years before psoriasis eventually appears! Conversely, patients can have psoriasis for over 20 years prior to development of arthritis, leading to the ultimate diagnosis of psoriatic arthritis.

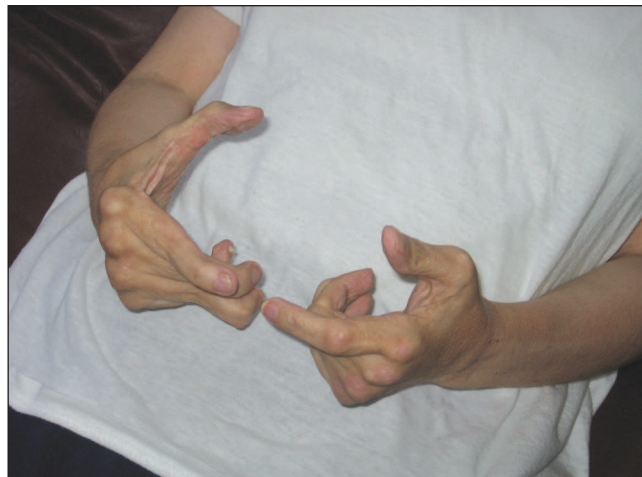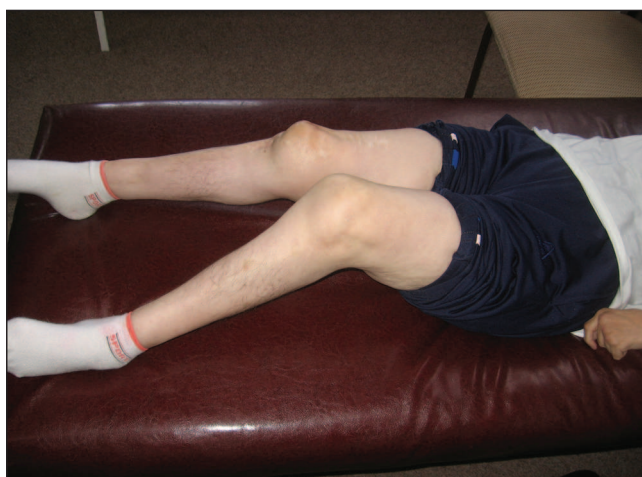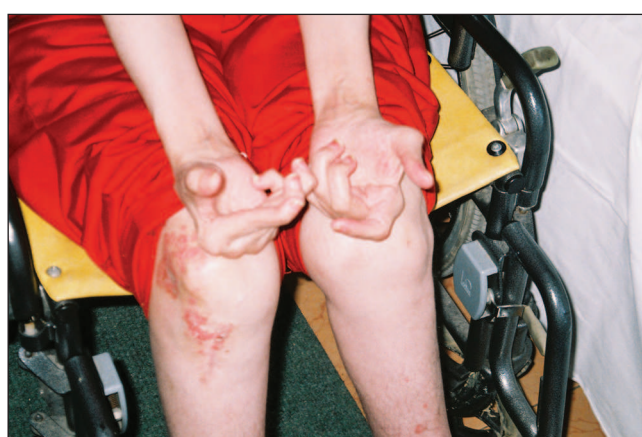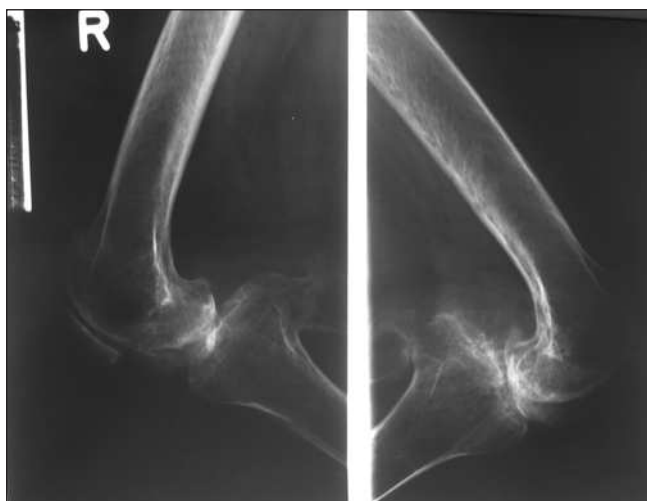
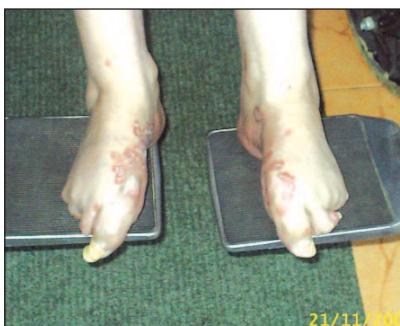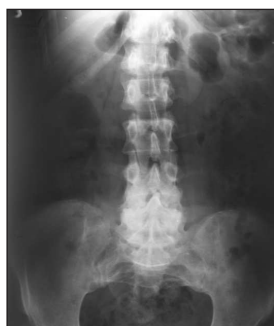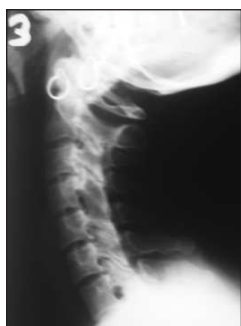Psoriatic arthritis is a systemic rheumatic disease that can also cause inflammation in body tissues away from the joints other than the skin, such as in the eyes, heart, lungs, and kidneys. Psoriatic arthritis shares many features with several other arthritic conditions, such as ankylosing spondylitis, reactive arthritis (formerly Reiter's syndrome), and arthritis associated with Crohn's disease and ulcerative colitis. All of these conditions can cause inflammation in the spine and other joints, and the eyes, skin, mouth, and vari-

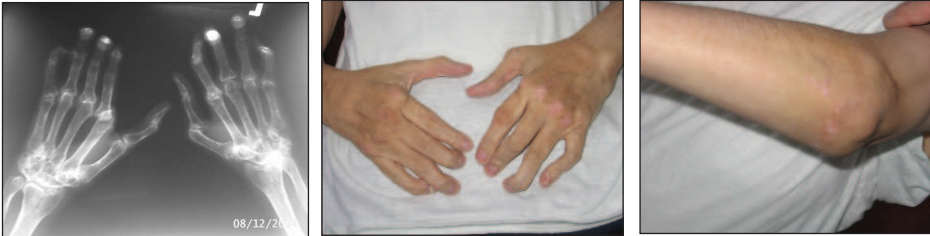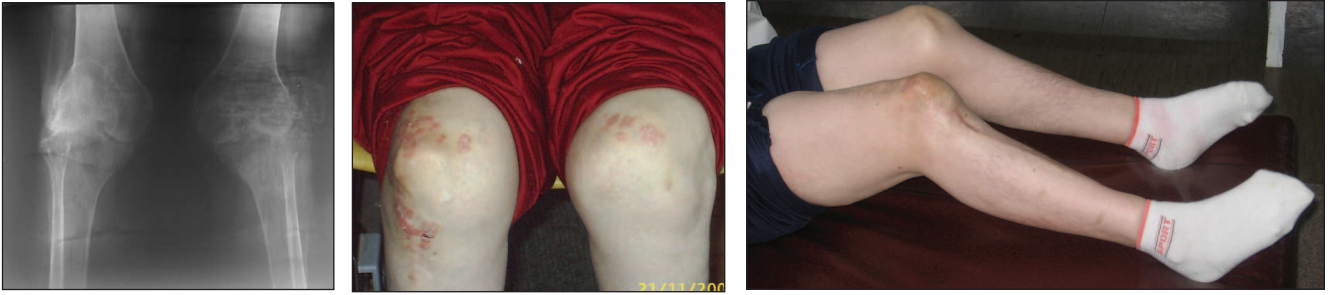
ous organs. In view of their similarities and tendency to cause inflammation of the spine, these conditions are collectively referred to as "spondyloarthropathies."

METHODS

Female patient, M.M. 38 years. She has had psoriasis since the age of 18 (1984). She has been treated by Kuterid and Diproderm, stayed in a hospital several times. She has had pain and stiffness in her knees since 1990, and she was treated with NSAID. In 1994, she was treated in a hospital due to advanced inflammatory changes in hips, knees and sacroiliac joints. After that she did not see her rheumatologist for 8 years. From 1995 to 1998, deformities with contractures in right then left foot, hands, elbows and knees were made. She has been unable to move since November

26, 1998. She denies disorders in other organ systems. The treatment with modifying medicines (MTX 10 mg) and glucocorticosteroids (Pronison 5 mg) was started in 2002, when she already had pronounced flexion contractures in all joints of arms and legs. At first rehabilitation in 2004, patient was in a wheelchair, dependant in transfer with definite contractures in all joints of arms and legs, fingers in ulna deviation, performs only tweezers' catch. General hypotrophy of muscles with muscle strength reduction. Psoriatic changes are present on nails, elbow skin, right knee, thoraco-lumbar spine and head. Sedimentation rate 22/45. Her rehabilitation plan was as following: kinesitherapy, paraffin, magnetic, photo, hydro and Horizontal, six days per week, once daily, for 30 days. No one in her family has had either psoriasis or arthritis.





RESULTS

Patient was put in vertical position for walk in parallel bars with additional knee stabilization, contractures of hips and knees were reduced, muscle strength in legs was improved, pain intensity in joints was reduced, psoriatic changes on skin are less pronounced, the patient has been motivated for continuing rehabilitation. The result maybe could be better that she came early in our rehabilitation center, for example 5 years ago. But now, she is more motivated and she is coming to rehabilitation every year.

CONCLUSION

Untreated disease due to passive attitude of the patient led to definite anatomically deformities, severe functional damages of joints and immediate invalidity.

Apstrakt

CILJ: Prikazati pacijentkinju sa nelečenim psorijaznim artritisom

METODOLOGIJA: Pacijentkinja M.M. stara 38 godina. Ima psorijazu od svoje 18-te godine (1984). Od 1995-1998 javili su se deformiteti sa kontrakturama na stopalima, šakama, ramenima i kolenima. Nije mogla da hoda od 26. Novembra 1998. Lečenje sa BML (MTX 10 mg) i kortikosteroidima (Pronison 5 mg) počela je 2002, kada je već imala izražene fleksione kontrakture na svim zglobovima ruku i nogu. Na prvu rehabilitaciju 2004. dolazi u kolicima, zavisna u transferima, sa kontrakturama u svim zglobovima, prstima u ularnoj devijaciji, imala je samo pincentni hvat. Opšta hipotrofija musculature. Psorijatične promene imala je na noktima, laktovima, desnom kolenu, torakolumbalnom delu kičme i glavi. Rehabilitacioni plan: kinesiterapija, parafin, magnet, Hioptron, hidro i Horizontalna terapija, šest dana u nedelji, jednom dnevno, ukupno 30 dana. Niko u familiji nije imao psorijazu ni artritis.

RESULTAT: Postavljena u vertikalni položaj za hod u razboju sa dodatnom stabilizacijom kolena, redukovane kontrakture u kukovima i kolenima, ojačana muskulatura nogu, smanjen intenzitet bola u zglobovima, psorijatične promene manje izražene, pacijent motivisan da nastavi sa rehabilitacijom.

ZAKLJUČAK: Nelečena bolesr dovodi do pasivnog stava pacijenta i do definitivnih anatomskih deformiteta, teških funkcionalnih oštećenja i invalidnosti.

REFERENCES

1. Pilipović N. Reumatologija. Zavod za udžbenike i nastavna sredstva, Beograd 2000:551-60

2. Peroni A, Gisoni P, Zanoni M, Girolomoni G. Balneotherapy for chronic plaque psoriasis at Comano spa in Trentino, Italy. *Dermatol Ther.* 2008;21(Suppl.1):S31-8.

3. Matz H, Orion E, Wolf R. Balneotherapy in dermatology. *Dermatol Ther.* 2003;16:132-40.

4. Schlessinger J. Spa dermatology: past, present, and future. *Dermatol Clin.* 2008;26:403-11.

5. Hollo P, Gonzalez R, Kasa M, Horvath A. Synchronous balneophototherapy is effective for the different clinical types of psoriasis. *J Europ Acad Dermatovenereol.* 2005;19:578-81.

6. Pavlica L, Perić-Hajzler Z, Jovelić A, Sekler B, Damjanović M. Psoriatic arthritis: a retrospective study of 162 patients. *Vojnosanit Pregl* 2005, 62 (9):613-20