

*Aktuelne teme/
Current topics*

AKTUELNE TEME/ CURRENT TOPICS
THE APPLICATION OF ULTRASOUND SCAN IN
TWIN PREGNANCY MONOCHORIONIC TWINS
AND THEIR PATHOLOGY

PRIMJENA ULTRAZVUČNOG SKENA
U BLIZANAČKOJ TRUDNOĆI– MONOHORIJATI
I NJIHOVA PATOLOGIJA

Aleksandar Grdinić¹, Snezana Crnogorac¹,
Sasa Raicevic¹ Gordana Vukcevic¹, Minja Stankovic²,
Goran Marjanovic¹ Aleksandra Grdinić³

Correspondence to:

Dr Aleksandar Grdinić,

Spec. of Gynaecology and Obstetrics,
Poliklinika KCCG
Clinical Center of Montenegro, Podgorica
Tel: +382 20 412 230
E-mail: aleksandrgrdinić@yahoo.com

¹Clinical Center of Montenegro, Podgorica

²University Clinic of Gynaecology and Obstetrics Narodni Front,
Belgrade

³Military Medical Academy, Belgrade

Key words

monochorionic, twins, ultrasound,
anomalies.

Ključne reči

monohorijati, blizanci, ultrazvuk,
anomalije.

Abstract

Zygoty refers to the type of concept and chorionicity indicates the type of placentation. No one knows exactly why division of zygote happens but what is certain is the fact that it is a deviation from the physiology, so it is not surprising that monochorionic twins are linked to diverse pathology. Frequency rate of occurrence of monochorionic twins is 1:250 births and usually does not depend on race, hereditary, age and parity, but it is strongly linked to the Assisted Reproductive Technology (ART).

Today it is clear that chorionicity better and more accurately than zygoty determines many aspects of prenatal management of pregnancy and its outcome with the posting guidelines and evaluation of obstetric risk. Therefore, chorionicity ultrasonic evaluation in the first trimester is the imperative. The period between the 10th and the 14th week of gestation is the „gold standard” for defining chorionicity. Chorion frondosum is thick enough to be seen between the two layers of amnion as a wedge-shaped, triangular, structure, making lambda sign (Y) or „twin peak” sign - which is a feature of dichorionic twins. On the contrary, if this tab of the chorion is not visible and there is a T sign between the layers of amnion, this will give a diagnosis of monochorionic twins.

Almost all monochorionic twins have vascular anastomoses in placenta, but there are important differences in number, size and direction of these, seemingly random and unsystematized connections. Anomalies specific to monochorionic twins: acardius, conjoined twins, twin to twin transfusion syndrome.

INTRODUCTION

It is estimated that 99.2% of spontaneous pregnancies are monofetal, while 0.8% of them are multifetal ones. However, the situation is drastically changed if Assisted Reproductive Technology is applied. Most frequently, twin pregnancies result in fertilization of two separate ova by two spermatozoids - dizygotic (fraternal) twins. In approximately 1/3 of cases, twins are the product of one ovum and one spermatozoid, which is later divided into two similar structures – monozygotic (identical) twins (1).

DISCUSSION

Zygoty refers to the type of concept and chorionicity indicates the type of placentation.

Depending on time of division, we have the following options:

1. During the first 72 hours chorion is not yet differentiated – dichorionic twins (DC) are formed, diamniotic twins.

2. Between the fourth and eighth day, chorion is differentiated but not amnion – monochorionic twins (MC) are formed, diamniotic twins.

3. After the eighth day, when monochorionic, monoamniotic twins are formed.

4. Division after the thirteenth day, i.e. upon formation of the embryonic disc – conjoined twins are formed.

No one knows exactly why division of zygote happens but what is certain is the fact that it is a deviation from the physiology, so it is not surprising that monochorionic twins are linked to diverse pathology.

Frequency rate of occurrence of monochorionic twins is 1:250 births and usually does not depend on race, hereditary, age and parity, but it is strongly linked to the ART methods.⁽²⁾

Today it is clear that chorionicity better and more accurately than zygosity determines many aspects of prenatal management of pregnancy and its outcome with the posting guidelines and evaluation of obstetric risk. Therefore, chorionicity ultrasonic evaluation in the first trimester is the imperative^(3,4).

Monochorionic twins are monozygotic, dichorionic twins of different sex are dizygotic, dichorionic twins of the same sex have unknown zygosity. Two-thirds of the monozygotes are monochorionic twins. Monochorionic twins are exposed to 2-3 times higher risk of structural anomalies.

Defining of amnionicity in monochorionic twins is not reliable before the 8th week of gestation. When in this gestation two fetuses are visible in parallel („head to head”), it should suspect that these are conjoined twins. Then it should identify the movements of twins by ultrasound probe: one opposite another, which is normal or one towards another, which deepens the doubt.

The period between the 10th and the 14th week of gestation is the „gold standard” for defining chorionicity. Corion frondosum is thick enough to be seen between the two layers of amnion as a wedge-shaped, triangular, structure, making lambda sign (Y) or „twin peak” sign - which is a feature of dichorionic twins⁽⁶⁾. On the contrary, if this tab of the chorion is not visible and there is a T sign between the layers of amnion, this will give a diagnosis of monochorionic twins.

Lambda sign in the DC evaluation has the sensitivity of 97% and specificity of 100%, a T sign in the definition of MC 100% and 98%^(5,6).

Determination of chorionicity by measuring thickness of intertwin dividing membrane and counting of its layers is less reliable. It depends on skill and experience of the doctor and the probe used. Ultrasound beam must be perpendicular to intertwin dividing membrane, not in parallel or at an angle, it will then look thinner and error will occur. The command „ZOOM IN” should be obligatory used. Thickness of 2 mm is a „cut off” (value).

After 16th week of gestation frondosum regresses and determination of chorionicity is less reliable (90%). „Y” sign disappears by merging of amnion and

chorion and if twins have the same sex, MC may be wrongly diagnosed⁽⁶⁾.

Therefore, an adequate ultrasound scan in the first trimester makes further checks during pregnancy only meaningful and much easier.

Measurement of the NT(nuchal translucency) between 11-13 +6 week of gestation in MC is very useful, not only because of the assessment of pregnancy risk against chromosomal abnormalities and cardiac defects, but also because the fact that increased NT may be an early TTTSy marker⁽⁷⁾.

Anomalies in twin pregnancy can be classified in several ways according to different criteria⁽⁸⁾. One classification could be, as follows:

1. Anomalies that occur more frequently in multifetal pregnancies are, as follows:

- neural tube defects,
- hydrocephalus,
- heart anomalies,
- esophageal atresia,
- anorectal atresia.

2. Postural defects, e.g. club foot.

3. Anomalies specific to monochorionic twins: acardius, conjoined twins.

4. Anomalies caused by placental malformations which are, as a rule, exclusive feature of monochorionic twins: TTTSy, velamentous cord insertion.

CONJOINED TWINS

The incidence rate is 1:200000 births i.e 1:40000. liveborns. These are monochorionic, monoamniotic twins⁽¹⁾.

The overall survival rate is 5-25%, and the most common karyotype is 46 xx, about 70%. They are often accompanied by heart anomalies (25%), neural tube defects, facial clefts, imperforate anus, polyhydramnios (about 50%).

Depending on their point of conjunction, they may be, as follows:

- anterior (thoracopagus),
- posterior (pygopagus),
- cephalic (craniopagus),
- caudal (ishiopagus)

A thorough ultrasound examination is essential for diagnosis and prognosis. It will give an answer where exactly the point of conjunction is and which organs are involved in share. If the vital organs are not involved in share, conjoined twins are compatible with life⁽⁹⁾.

VASCULAR ANASTOMOSES

Almost all monochorionic twins have vascular anastomoses in placenta, but there are important differences in number, size and direction of these, seemingly random and unsystematized connections.

Artery-to-artery connections are at the surface of the chorion and are present in 75% of monochorionic twins and represent the most common model.

Vein-to-vein and artery-to-vein connections are almost equally present in about 50% of monochorionic placentas.

Artery-to-vein connections are the most important ones with the highest pathological potential. They are spread over the capillary bed of the villous space, forming the third circulation.

ACARDIAC TWIN (TRAP) (twin reversed arterial perfusion sequence)

Acardiac twin was first verified by ultrasound in 1978 (10). The incidence rate is 1:35000 births that is very rare but extremely severe complication of monochorionic twins.

Due to the paradoxical (reversed) perfusion by structurally normal „pump twin” developmental disorders appear in the second twin, with signs of heart failure of the „pump” and severe disorders in development and growth of the recipient (figure 6), which may have more pictures: acardius acephalus, acardius myelacephalus and acardius amorphus.

The main guide for the diagnosis is continuous growth of the „apparently dead” twin (negative heart action), through several successive examinations. Sometimes, due to the existence of a heart rudiments and /or pulsations transmitted from „pump twin”, it is possible to make a wrong conclusion that heart action exists which causes the correct diagnosis to be omitted.

In a few cases the diagnosis was made in the first trimester, suggesting that the basis of pathogenesis is heart dismorphogenesis that leads to reverse flow, rather than cardiac agenesis, because heart action was verified in the 7th gestation week.

Two blood vessels in the umbilical cord are the rule.

Ultrasonic bad prognostic signs are: discordant growth (70% or more), hydrops, polyhydramnios, acardius with hands, reduced resistance of the arteria umbilicalis (RI-resistance index of the arteria umbilicalis is lower than 0.20).

If not treated, the „pump twin” will be sentenced to death in 50-75%.

Therapeutic measures include discontinuation of vascular communication between twins. This can be achieved by:

- Transabdominal fetoscopic cord ligation of acardiacus

- Ultrasonically controlled cauterization of umbilical cord blood vessels by radiofrequency ablation needle.

TWIN TO TWIN TRANSFUSION SYNDROME (TTTSy)

The incidence rate is 1:400 pregnancies and approximately 25% of monochorionic twins have some of the clinical manifestations and account for 17% in perinatal mortality.

It occurs mainly in diamniotes and typically develops in mid-gestation.

According to some authors, the etiology is related to the existence of deep arteriovenous anastomoses in the placenta of the monochorionic twins. However, other authors explain it as a complication of velamentous insertion of the umbilical cord, which leads to uneven perfusion, because it is easily to be compromised.

In recent years, computer models have found that the direction of blood flow is determined by arterial pressure of „donor”, not by the number of anastomoses (11).

By definition, this syndrome affects structurally normal fetuses. Blood is transmitted such as transfusion from „donor” twin to the „recipient” twin. Donor becomes anemic, with signs of delay in growth and oligoamnions (figure 7). Recipient becomes polycythemic with a picture of hydrops and polyhydramnios (figure 8). Prenatal diagnosis is problematic. It is aimed to prevent fetal morbidity and mortality using ultrasound as a method of choice to sort the fetuses out to those who should undergo in utero prenatal therapy and those determined for delivery as a therapeutic measure.

In 1990 Bickestein established the ultrasound as a crucial method in screening and diagnostics of TTTSy.

The criteria are as follows:

1. Confirmation that twins are monochorionic (T sign, intertwin membrane is thinner than 2 mm, the same sex).

2. Discordant growth (over 20% weight difference - „cut off” is the difference of 20 mm in AC(abdominal circumference) of twins).

3. Oligoamnions of the donor (largest vertical pocket is shorter 2cm). Polyhydramnios of the recipient (the largest vertical pocket is longer than 8cm).

4. Abnormalities established by Doppler findings:

- reduced or reverse flow through ductus venosus during the atrial contraction as well as umbilical vein pulsation in the recipient.

- abnormalities, i.e. pathological model of filling during right ventricular diastole, prolonged time of isovolumic relaxation and pathologic flow through the vein cavu inferior and ductus venosus (Myocardial performance index).

The prognosis is very dubious. Invasive methods, such as AC (amniocentesis) and CC (cordocentesis) are usually applied in order to evaluate donor's fetal

anemia (4). However, today, we are increasingly turning to non-invasive procedures such as measurement of PSV (Peak Systolic Velocity) of the arteria cerebri media. The risks include central nervous system damages caused by hypotensive ischemia; prenatal death of one twin and damage in survivor, also caused by hypotensive necrosis and neonatal death due to preterm delivery.

The therapy involves serial amnioreduction, septostomies, laser ablation of vascular anastomoses and selective fetocide.

CONCLUSION

Twin pregnancy causes double joy for future parents, because instead of one, they expect two angels to fill their home. However, at doctors in charge of managing the related pregnancy, only the caution and anxiety are double increased. Due to the increased number of structural anomalies and specific syndromes (conjoined twins, TRAP sequence and TTTS), monochorionic twins are largely responsible for this fear. These pregnancies are followed by increased morbidity and mortality rates. Therefore, by appropriate use of ultrasound, especially in the first trimester of pregnancy, we can significantly contribute to timely identification of problems and thus increase the chances for a good outcome.

*Figure 1
Chorionicity*

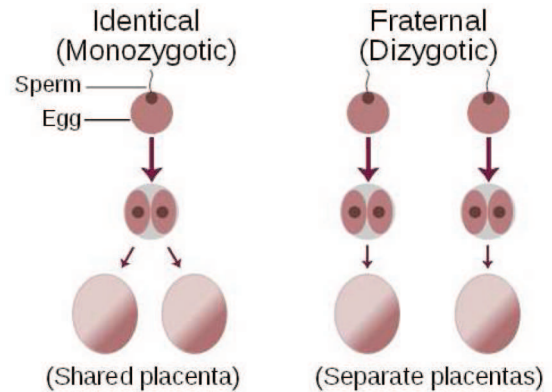
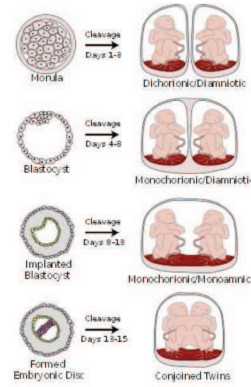


Figure 2 : Zygosity

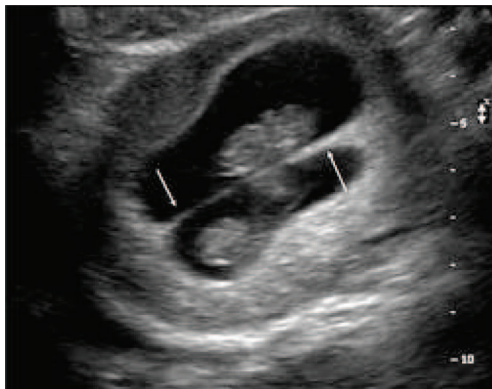


Figure 3: Y(twin peak) sign

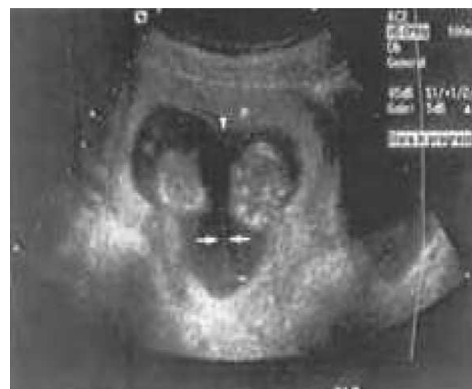

Figure 4: T sign

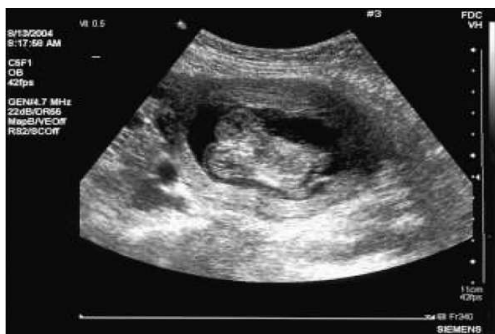

Figure 5: Conjoined twins

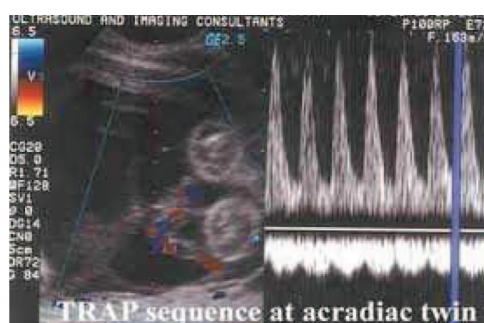
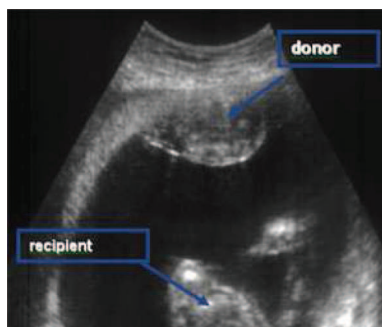
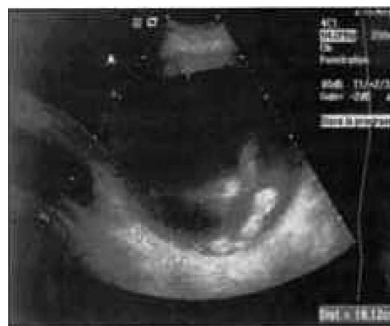

Figure 6: TRAP sequence at acardiac twin



*Figure 7: TWIN TO TWIN TRANSFUSION SYNDROME (TTTSy)
Donor becomes anemic, with signs of delay in growth and oligoamnions.*



*Figure 8: TWIN TO TWIN TRANSFUSION SYNDROME (TTTSy)
Recipient becomes polycythemic with a picture of hydrops and polyhydramnios.*

Apstrakt

Zigocitet se odnosi na tip koncepcije, a horionicitet označava vrstu placentacije. Ne zna se tačno zašto dolazi do podjele zigota ali ono što je sigurno je činjenica da je to odstupanje od fiziologije, pa ne čudi zašto su monohorijadni blizanci skopčani sa šarolikom patologijom. Frekvencija javljanja monohorijata je 1:250 rođenih i uglavnom ne zavisi od rase, nasleda, godina života i pariteta ali je jako povezana sa metodama Asistirane Reproductive Tehnologije (ART).

Danas je jasno da horionicitet bolje i preciznije nego zigocitet determiniše brojne aspekte prenatalnog vođenja trudnoće i njenog ishoda sa postavljanjem smjernica i procjenom akušerskog rizika. Zbog toga se ultrazvučna procjena horioniciteta u prvom trimestru postavlja kao imperativ. Vrijeme između 10 i 14 tjedna je „zlatni standard“ za ultrazvučno definisanje horioniciteta. Chorion frondosum je dovoljno debeo da bi se vidio između dva sloja amniona kao klinasta, trouglasta, struktura praveći lambda (Y) ili twin peak znak što je obilježje dihorijata. Ako se naprotiv, ne vidi taj jezičak horiona između listova amniona imamo T znak, što daje dijagnozu monohorijata.

Skoro svi monohorijati imaju vaskularne anastomoze u posteljici, ali postoji bitna razlika u broju, veličini i smjeru ovih naizgled nasumičnih i nesistematskih konekcija.

Anomalije specifične za monohorijate su: conjoined twins, acardius, twin to twin transfusion syndrome.

REFERENCES:

1. Derom C, Derom R. The East Flanders Prospective Twin Survey. In: Blickstein I, Keith LG (eds) Multiple pregnancy, 2nd edition; London, UK. Taylor and Francis 2004:39-47.
2. Blickstein I. Estimation of iatrogenic monozygotic twinning rate following assisted reproduction: pitfalls and caveats. Am J Obstet Gynecol 2005; 192(2):365-8.
3. Tong S, Vollenhoven B, Meagher S. Determining zygosity in early pregnancy by ultrasound. Ultrasound Obstet Gynecol 2004;23:36-7.
4. Bromley B, Benacerraf B. Using the number of yolk sac to determine amnionicity in early first trimester monochorionic twins. J Ultrasound Med 1995 ;14 :415-419
5. Finberg HJ. The 'twin peak' sign: a reliable evidence of dichorionic twinning. J Ultrasound Med 1992 ;11 :571-577
6. Sepulveda W, Sebire NJ, Hughes K, Odibo A and Nicolaides KH. The lambda sign at 10-14 weeks of gestation as a predictor of chorionicity in twin pregnancies. Ultrasound Obstet Gynecol 1996 ;7 :421-423
7. Sebire NJ, D'Ercole C, Hughes K, Carvalho M, Nicolaides KH. Increased nuchal translucency thickness at 10-14 weeks of gestation as a predictor of severe twin-to-twin transfusion syndrome. Ultrasound Obstet Gynecol 1997; 10: 86-89.
8. Benirschke K, Kim CK. Multiple pregnancy. N Engl J Med 1973;228:1276-84.
9. Sebire NJ, d'Ercole C, Carvalho M, Sepulveda W, Nicolaides KH. Inter-twin membrane folding in monochorionic pregnancies. Ultrasound Obstet Gynecol 1998;11:324-327.
10. Cynthia Lehr, John Dire. Rare occurrence of a holoacardious acephalic monster: Sonographic and pathologic findings. Journal of Clinical Ultrasound 1978; 6:259-261.
11. Sebire NJ, Souka A, Skentou H, Geerts L, Nicolaides KH. Early prediction of severe twin-to-twin transfusion syndrome. Human Reprod 2000 ;15 :2008-10.

■ The paper was received and accepted on 26.03.2012.