

*Prikazi bolesnika/
Case reports*

A SEVERE CASE OF PARAPHARYNGEAL
ABSCESS TREATED AS A SPASTIC
TORTICOLLIS

TEZAK SLUČAJ PARAFARINGEALNOG
APSCESA TRETIRANOG KAO SPASTIČNI
TORTIKOLIS

Correspondence to:

dr **Milan Erdogljija**
ORL Klinika VMA
Ul.Crnotravska 17

E-mail: milan.erdogljija@gmail.com

Milan Erdogljija, Jelena Sotirovic, Ugljesa Grgurevic,
Nenad Baletic

ENT Clinic, Military Medical Academy, Belgrade

Key words

parapharyngeal abscess, torticollis,
odinophagia, dysphagia, trismus, ervej,
incision, drainage

Ključne reči

parafaringealni apsces, tortikolis,
odinofagija, disfagija, trizmus, ervej,
incizija, drenaža

Abstract

Parapharyngeal abscess is the second most common deep neck infection. It is usually a secondary infection develops from oropharyngeal infection. Parapharyngeal abscess complications are numerous and potentially lethal. The diagnosis makes clinically and radiologically with CT scan. The cause is poly bacterial infection. The treatment must be aggressive with antibiotics and surgery. It starts with the combined intra venous broad-spectrum antibiotics. Surgically drainage of abscess should be done through external or internal incision with repeated procedures after 24h and 48h. The correction of antibiotic treatment is necessary according to swab results of evacuated pus. Control CT scan should be done one month after finished medical treatment.

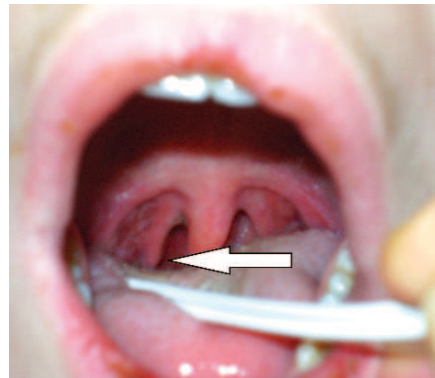
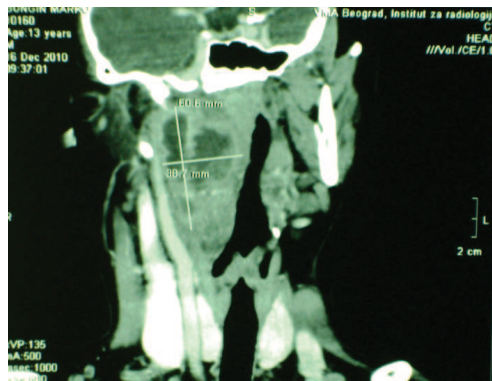

INTRODUCTION

Parapharyngeal abscess is encapsulated purulent, deep soft tissue infection of parapharyngeal space, potentially life-threatening. Worldwide incidence is 1 in 6-10000 people every year (1). Parapharyngeal abscess is the second most common deep neck abscess, after peritonsillar abscess (2). Parapharyngeal space is defined as inverted pyramid, the base coinciding with skull base on petrous part of temporal bone and the apex located at the greater corn of the hyoid bone. The styloid diaphragm divides the parapharyngeal space into two compartments; prestyloid and poststyloid space. Poststyloid space contains large blood vessels of the neck: internal carotid artery and internal jugular vein with associated lymph nodes and nerves (the last 4 cranial nerve and sympathetic trunk). Carotid sheath passes through poststyloid space and it's represents a way of spreading infection caudally in the neck and mediastinum. Parapharyngeal infections arises by spreading infection 'per continuitatem' or through blood from tonsillitis, peritonsillar abscess, infection of tonsillar lodge after tonsillectomy, the expansion process of mastoiditis and petrositis, teeth processes and trauma of the neck and throat. The cause is poly bacterial and usually reflects the oropharyngeal bacterial flora. They are mainly isolated streptococcus sp. and staphylococcus sp. and often anaerobic bacterial flora too, which lead to the particular severity of infections. Group A streptococcus remains

a significant cause of head and neck infections in children (9). Abscesses in children 1 year or older affected parapharyngeal region, yielding group A streptococcus and for children younger than 1 year old yielding S.aureus (7). In immunocompromised persons, a wide variety of microorganisms can be isolated. However, when abscess is formed, antimicrobial therapy is effective only in conjunction with adequate surgical drainage (6). Complications of untreated parapharyngeal abscesses are multiple (3). Mediastinitis is the most common complication and can lead to lethal outcome. The strong parapharyngeal edema can lead to airway obstruction. Vascular complications such as bleeding after ruptured internal carotid artery can be fatal also. Thrombosis of internal jugular vein with septic emboli formations can lead to pulmonary embolism or abscess, cavernous sinus thrombosis, brain abscess, meningitis and sepsis.

CASE REPORT

12 years-old boy was admitted as an urgent case and treated in Clinic for ear, nose and throat in the Medical Military Academy. The patient was admitted highly febrile with temperature 39.3°C, with weakness, pain in the neck and forced head position displaced to the right, odinophagia and dysphagia, without trismus. Previous 17 days he was treated by pediatricians and physiatrists diagnosed as spastic torticollis. Although he was febrile every day to 38.3°C, he



received only pain killers. Clinical findings on admission were typical. Oral examination revealed that patient had no trismus, but there were throat hyperemia, anterior palatal arch asymmetry, medially displaced right palatal arch, swollen and painful on palpation, with palatal tonsils in the level of palatal arches bilaterally. There were touchable and painful two large swellings on the neck, moving to the ground, in the right II and III neck regions the first, measuring up to 5cm in diameter and the second in the right V neck region, measuring up to 4cm in diameter. Blood tests showed a high level of leukocytes $26,4 \times 10^9/l$ predominate by neutrophils 77% and high CRP-114. MSCT scan showed in the level of the oropharynx and epipharynx, on right parapharyngeal space big, oval tumor $36 \times 39 \times 60$ mm with signs of central necrosis and peripheral contrast repeater. In the upper jugular chain there were several necrotic lymph nodes up to 18mm in diameter around the described tumor. There were no reliable signs of compression or thrombosis in the right internal jugular vein. Many enlarged lymph nodes of jugular chain were noticed on both side of the neck, predominately on the right side, the largest one dimension of 31×22 mm. US of the neck showed also along the right jugular chain many oval lymph nodes, homogeneous hypoechogenic structure, with a maximum diameter of 35×15 mm in a space of jugulodigastric triangle. There were less enlarged lymph nodes in submandibular region on the both sides of the neck and on the right side in parotid region. No signs of thrombosis of the internal jugular vein, neither stenosis nor occlusion of external and internal carotid artery were noticed. Broad-spectrum intra venous antibiotics were administrated (ceftriaxon and metronidazole). Under general aesthesia intraoral vertical incision is made on the lateral pharyngeal wall, right behind the posterior palatine arch in the area of highest prominence of parapharyngeal abscess. Pus was drained and swab was analyzed: *Streptococcus B haemoliticus*, *Acinobacter haemoliticus* and large number of leukocytes. Antibiotics were prescribed according to swab findings (benzyl penicillin and metronidazole). Drainage of parapharyngeal abscess through intraoral incision was re-made after 24 hours. Three days after admission the patient was with normal temperature. The 7th postoperative day patient was realized from hospital and went home with oral antibiotic therapy (phenoxymethylpenicillin) another 7 days. Clinical evaluation after one month was with no significant abnormalities, with normal local findings, blood test and normal control MSCT scan.

1. Patient look after admission to hospital
2. MSCT scan - coronal section; parapharyngeal abscess on the right side; diameter 60×39 mm
3. Oropharyngeal findings two days after intraoral vertical incision on the lateral wall of mesopharynx, behind posterior palatine arch on the right side (arrow) and parapharyngeal abscess drainage.

DISCUSSION

Crooked neck or torticollis is a deformity of neck with laterally displaced head to one side and with turned face to the other side. Crooked neck can be congenital- since birth, or that can occurs later- acquired. Differential diagnosis of acquired torticollis can be caused by various causes. Deformity can occur during life because of problems with vision (diplopia for example), withered muscles of the neck due to muscle contracture in spastic torticollis (4) or scars on the skin caused by burns or injuries. Crooked neck can occur as a result of inflammation of the lymphatic vessels and lymph nodes, or fascia, inter fascia space and content of surface and deep region lateral side of the neck. Some spine deformities can result in distortion of the neck or bad posture of body without deformity can lead to crooked neck. Some mental illnesses (hysterical torticollis) and nerve stimulation of muscles disorders can be reason for torticollis. Rheumatic disease, tuberculosis (Pots disease) and neck injuries can also be the cause of crooked neck.

The appearance of torticollis depends on the difference of degree of pathologic substrate in findings on the neck from side to side. The head is lateral displaced to the affected side (ipsilateral shoulder), and the face looks towards the healthy side and upwards. Therapeutic treatment of torticollis depends on cause of torticollis. Palpation of the neck can determined existing of some different swellings, enlarged lymph nodes, abscesses, etc... Careful inspection and palpation in children with fever and neck masses, especially in young children should be done (8). That examination is more difficult in fat children with torticollis, so it should be combined with ultra sound of the neck. Careful examination of throat is obliged and to do blood tests to. In severe cases with suspicion of deep neck infections computer tomography of the neck should be done. CT scan is also indicated to assess the extent of infection and exclude complications (5).

CONCLUSION

Parapharyngeal abscess is a severe deep neck infection, potentially a life-threatening. Torticollis is only one of the symptoms in clinical findings of parapharyngeal abscess. Spastic torticollis, which is the most common form, is a benign deformity- harmless for life. If parapharyngeal infec-

tion is suspected, do blood test, ultra sound of the neck, possibly cervical CT scan and a multidisciplinary approach, with pediatric examination, neurologist, physiatrist, ENT and infectologist.

Apstrakt

Parafaringealni apsces je druga po učestalosti duboka infekcija vrata. Najčešće se sekundarno razvija iz orofaringealne infekcije. Komplikacije parafaringealnog apscesa su mnogobrojne i potencijalno letalne. Dijagnoza se postavlja klinički i radiološki uz pomoć CT. Uzročnik je polimikrobna flora. Terapija mora biti agresivna antibiotska i hirurška. Počinje se kombinovanom parenteralnom antibiotskom terapijom širokog spektra. Drenaža apscesa putem spoljne ili unutarnje incizije sa ponovljenim procedurama evakuacije gnoja posle 24h i 48h. Prema biogramu i antibiogram brisa evakuisanog gnoja korigovati antibiotski tretman. Kontrolni CT uraditi mesec dana nakon izlječenja.

REFERENCES

1. Herzon F, Martin A, Medical and surgical treatment of peritonsillar, retropharyngeal and parapharyngeal abscesses. *Curr Infect Dis Rep* 2006; 8(3):196-202
2. Page C, Biet A, Zaatari R, Strunski V, Parapharyngeal abscess: diagnosis and treatment. *Eur Arch Otorhinolaryngol* 2008; 265(6):681-6
3. Alaani A, Griffiths H, Minhas S, Olliff J, Lee A, Parapharyngeal abscess: diagnosis, complications and management in adults. *Eur Arch Otorhinolaryngol* 2005; 262(4): 345-350
4. Korneychuk A, Muavadi I, Torticollis spastica (a review), *Zh. Nevrol. Psichiatr. Im S.S. Korsakova*, 1994;94(1):96-101
5. Federici S, Silva C, Marechal C, Laporte E, Sevely A, Groueteau E, Claudet I, Retro- and parapharyngeal infections standardization of their management. *Arch Pediatr*. 2009;16(9):1225-32.
6. Brook I. Microbiology and management of peritonsillar; retropharyngeal and parapharyngeal abscesses. *J Oral Maxillofac Surg*. 2004;62(12):1545-50.
7. Coticchia J, Getnick G, Yun R, Arnold J, Age-, site-, and time-specific differences in pediatric deep neck abscesses. *Arch Otolaryngol Head Neck Surg*. 2004;130(2):201-7.
8. Chang L, Chi H, Chiu N, Huang F, Lee K, Deep neck infections in different age groups of children. *J Microbiol Immunol Infect*. 2010;43(1):47-52.
9. Cabrera C, Deutsch E, Eppes S, Lawless S, Cook S, O'Reilly R, Reilly J, Increased incidence of head and neck abscesses in children. *Otolaryngol Head Neck Surg*. 2007;136(2):176-81.