

*Opšti pregledi/
General reviews*

EHLERS-DANLOS SYNDROME AND ITS
OTOLOGIC & AUDIOLOGIC ATTRIBUTES*

Correspondence to:

Ali A. Danesh, Ph.D. Professor &
Director of Audiology Clinic,
Department of
Communication Sciences and Disorders
& Associate Professor of Clinical
Biomedical Sciences, Schmidt College
of Medicine, Florida Atlantic University
777 Glades Road, P.O. Box 3091
Boca Raton, Florida 33431-0991
+1.561.297.2071 (office)
+1.561.297.2258 (Clinic)
+1.561.297.2268 (Fax)
E-mail: danesh@fau.edu
<http://www.coe.fau.edu/faculty/danesh/>

EHLERS-DANLOS SINDROM
I NJEGOVE OTOLOŠKE I AUDIOLOŠKE
KARAKTERISTIKE*

Ali A. Danesh², Helene Sohne¹, Robert Pineyro³

¹ Department of Communication Sciences and Disorders,
Florida Atlantic University, Boca Raton, Florida, USA 33431

² Labyrinth Audiology, Inc., Boca Raton, Florida, USA 33486

³ ENT Specialist, Boca Raton, FL, USA 33428

* Invited paper / Rad po pozivu

Key words

Ehlers-Danlos Syndrome; hearing
loss; gene mutation;
clinical collaboration

Ključne reči

Ehlers-Danlos sindrom; gubitak sluha;
mutacija gena; saradnja između lekara

Abstract

Ehlers-Danlos Syndrome (EDS) is described as a genetically heterogeneous group of inherited disorders of connective tissue that interfere with the functioning of skin, joints, ligaments, blood vessels and multiple internal organs and systems. Typically, the syndrome manifests severe skin hyperelasticity and widened atrophic scarring and bruising, joint hyperlaxity and hypermobility. Human auditory and vestibular systems have many components with connective tissues. Such tissues include auricle, tympanic membrane, synovial joints of the middle ear and the connective tissue within the inner ear. Therefore, it is very likely to see auditory and vestibular involvement in individuals with EDS.

Ehlers-Danlos Syndrome (EDS):

This syndrome was first described in 1901 by Ehlers and subsequently in 1908 by Danlos, as cited in Thomas, Wright, Soucek, & Shalom, 1996 [1]. Those affected by EDS have skin extensibility, hypermobility of joints and fragile tissues [2]. Tofts, Elliott, Munns, Pacey & Silence [3] conducted a review of 3330 publications relating to the diagnosis of joint hypermobility and instability. The authors found inconsistencies related to usage and definition of terms such as „hypermobility”, „hyperlaxity” and „hyperextensibility” by some authors. Characteristics of EDS and Related Cutaneous Diseases were described by Abdelmalek, Gerber and Menter in 2002 [4]. They reported that many cutaneous syndromes share comorbidity with cardiovascular disease or dysfunction of multiple organ systems. Some of the effects of EDS include blue sclera, prominent epicanthic folds, alterations of the cornea or retinal detachment, lop ears, uncoordinated tongue movements, and a variety of orthopedic and neurologic involvements [5] and bleeding complications [6]. Premalatha, Sarveswari & Lahiri [7] identified two clinical signs associated with Ehlers-Danlos syndrome - Gorlin sign and Metenier sign. Gorlin sign is the ability to touch the tip of the nose with the tongue and Metenier sign

is when the subject has the ability of the easy eversion of the upper eyelid. Additionally, atrophic cigarette paper scarring is another characteristic of EDS [7]. Abnormalities of fibrillar collagen types I, III and V and enzymatic deviations in collagen processing have also been reported in several EDS subtypes [8].

EDS has at least six subclasses. According to Baumann, Giunta, Krabichler et al. [9] the mode of inheritance, the natural history and the heterogeneity of the six EDS types differ. Fatigue, distension of tendons, decreased motor coordination due to sparse intramuscular connective tissue and decreased exercise because of joint instability and/or weak connective tissue surrounding the muscle spindles are common symptoms of various types of EDS. Neuromuscular symptoms in EDS may in part be due to mild to moderate myopathy and/or neuropathic changes that have been attributed to the altered composition of the extracellular matrix in muscle and peripheral nerve.

During the mid-20th century, the clinical and genetic heterogeneity of EDS syndromes became evident, and with the improvement of biochemical and molecular techniques, a range of defects in collagen proteins and collagen-modifying enzymes were discovered in various forms of EDS. Early diagnosis by means of biochemical and molecular testing

became feasible for most EDS variants, proving to be an important component for adequate follow-up and genetic counseling [8]. There is no definitive treatment for Ehlers-Danlos syndrome. Symptoms must be managed and surgical repairs performed with caution when conditions reach critical levels. Surgical problems are exasperated due to tissue and capillary fragility leading to excessive bruising, frequent hernias and hemorrhaging, postoperative complications associated with wound dehiscence, hematoma, infection and coronary issues.

Speech and Swallowing Disorders in EDS:

The first assessment of EDS speech and hearing related problems occurred two decades ago. As cited by Hunter, et al. [10] a large group of patients with Ehlers-Danlos syndrome presented with hearing, speech, voice and language difficulties. Hunter, a speech therapist, recognized a glaring absence of literature for this population. A questionnaire was mailed to 411 members of the national EDS support group. Members who presented with EDS types I, II, III, IV and VI were representative groups for returned surveys. The return rate was greater than 50%, mean age of 45.5 years of age, and more females than males. Thirty nine percent of the respondents reported swallowing difficulty. Swallowing was the most commonly reported symptom. Problems included difficulty clearing throats on one swallow or tightness in the pharynx during swallowing. Relief was associated with soft food diets while others refused to eat alone for fear of choking. Chewing problems, jaw alignments, temporomandibular joint problems and orthodontic issues were prevalent in EDS cases.

Based upon Hunter et al. [11] survey results, speech challenges occurred at a higher rate in EDS samples than in the general population. Twenty eight percent reported inability to shout. Dysphonia was identified at a rate of 27% in the EDS population as opposed to general populations where it occurred at 28 out of 100,000. At the time when Hunter et al. [11] article was published (1998), speech and language difficulties were estimated at a rate of 1100 per 100,000 (1%) in pre-school and school-age children. EDS diagnosed individuals reported speech and language impairments at a rate of 48% (157 out of 327) in similar aged peer group. Voice fatigue, poor quality, and limited pitch range were salient features of subjects from age 11 onward. Mean age of onset was 36. Prevalence of speech and swallowing difficulties in EDS may suggest a link to the connective tissue issue.

Hearing Loss in individuals with EDS:

A review of the current literature revealed many articles reporting the conjunction of EDS and hearing impairment. Some of these investigations are just single case studies while others report mutations in EDS individuals with associated hearing impairments.

Miyajima et al. [11] reported a case of a 24 year old woman with conductive hearing loss due to otosclerosis and scar tissues at the proximity of the malleus and incus. The condition was caused by EDS related otitis media. The patient had been treated with otitis media and effusion since childhood. Tympanic membrane inspection was normal in the left ear, however, appeared retracted in the right ear.

Pathological deviations presented for the right ear and small lucent areas were visible anterior to the oval window in both ears, compatible with otosclerosis. Subsequent to stapes mobilization and scar tissue removal, hearing improved temporarily for a short few months. Deteriorated with newly formed scar tissue, infection inflammation, and conductive hearing loss followed. Miyajima et al. [11] suggested that, when hearing loss occurs in EDS patients, it is likely attributed to otosclerosis or retraction of the tympanic membrane. Mair et al. [12] and Mair [13] have studied otosclerosis in this population and reported a 27 year old female with increasing hearing loss due to otosclerosis, diagnosed with EDS, who experienced successful stapedectomy but exhibited recurrent facial palsy post-surgery.

Thomas et al. [1] reported a 62 year old man with bilateral conductive hearing losses due to retraction of the tympanic membrane. This man had been diagnosed with EDS and Melkersson-Rosenthal syndrome. Treatment included bilateral insertion of Shah aural grommets but hearing deteriorated due to excessive discharge. Subsequently, the patient underwent three insertions of Shah Permavent tubes. Chronic inflammatory granulation tissue prompted hearing deterioration. A three year treatment plan of tube removal and removal of granulation tissues, suction and silver nitrate application, resulted in healing of tympanic membrane and return to hearing capabilities of three years earlier. The patient was fitted with a postaural hearing aid for left ear. The authors hypothesize that flabby tympanic membranes and ossicular ligaments followed by wound infection, granulation tissue and pseudotumor formation were not related to specific collagen deficit. They believe that foreign bodies should be avoided in cases of clients with EDS and hearing loss to avoid the likelihood of infection. Hearing aids present a more favorable resolution in the absence of serious ontological disease in the opinion of these authors.

The results of the aforementioned surgical cases suggest that even conservative options should be approached with caution with patients with EDS and otosclerosis [11]. In the case of recurrent facial palsy [12, 13] and the chronic inflammatory granulation tissue following insertion of ventilation tube [1], this data strongly suggests that foreign bodies may be contraindicated for patients with EDS. The third patient underwent the surgical procedure for stapes mobilization and scar tissue removal which resulted in temporary improvement in hearing. Hearing deteriorated thereafter, likely due to re-fixation of the ossicles.

Baumann et al. [9] reported an autosomal-recessive variant of EDS with kyphoscoliosis and normal urinary LP/HP ratio in six individuals from five unrelated families from varying European descents. This disorder resembled clinical features of EDS VIA but also presents with sensorineural hearing loss. The work of Baumann et al. [9] revealed the presence of a FKBP14 mutation and it recommended a genetic analysis in all individuals with apparent kyphoscoliotic type of EDS and especially when EDS is associated with sensorineural hearing impairment. In conclusion, an autosomal-recessive variant of EDS caused by mutations in FKBP14 and the wide spectrum of clinical features in this condition may be due to a disturbance of protein folding in

the ER affecting one or more components of the extracellular matrix in various body parts and organs such as joints, ligaments, skin, vessels, ear, eye, and muscle.

Al-Owain et al. [14] reported a consanguineous family of five patients affected with Brittle cornea syndrome (BCS) and severe kyphoscoliosis. Patients characteristically demonstrated thin velvet-like skin, hallux valgus (Bunion Deformity), variable sensorineural hearing loss, and arachnoidactyly (spider-like, extra-long fingers). One patient had phenylketonuria (gene mutation re: inability to break down amino acid called phenylalanine) with milder ophthalmological and musculoskeletal phenotype than the siblings. Urinary pyridinoline and deoxypyridinoline concentrations were mildly elevated indicating increased bone collagen turnover. A new homozygous 14 bp duplication in exon 2 of Zinc-Finger469 gene (ZNF469) was uncovered by direct sequencing. Other characteristics included blue sclera, keratoconus, keratoglobus, chestnut hair and hypermobility of joints. This family highlights the phenotypic overlap between BCS and EDS. The overlap of clinical manifestations related to joints, skin and eyes between Ehlers-Danlos syndrome type VI and Brittle cornea syndrome (BCS), with variants in ZNF469 regulates development and maintenance of corneas. In addition to corneal fragility associated with BCS, patients had variable joint hypermobility and kyphoscoliosis, as well as mixed sensorineural conductive hearing loss. Three connective tissue disorders were described: EDS VI, osteogenesis imperfecta and Marfan syndrome [15]. Ocular rupture is less frequent in EDS VI than in BCS. It is scleral rather than corneal [16]. Elevated urinary excretion of pyridinium is consistent with increased diagnostic marker for EDS VI which is a result of recessive mutations in PLOD1 and can lead to life threatening vascular rupture [17]. The molecular basis of the disorder explains the phenotype and systemic manifestations. A missense mutation (mutation that changes codon for one amino acid into codon for a dif-

ferent amino acid) affecting the fourth of the five zinc finger domains of ZNF469 was reported in two Norwegian siblings with BSC, velvety skin, chestnut hair, scoliosis, dental anomalies, hearing loss and minor cardiac defects [18]. Al-Owain et al. [14] concluded from this research that the limited number of ZNF469 mutations did not suggest specific genotype/phenotype correlations. They did, however, suggest that BCS be considered in the differential diagnosis of EDS with prominent Ocular manifestations to facilitate molecular diagnosis.

One of the similar conditions to EDS is Osteogenesis Imperfecta (OI). OI is a defect or deficiency in collagen of which four distinct collagen I-related types are described [19]. Besides brittle bones, the clinical characteristics of OI subtypes include muscle weakness, exercise intolerance, hearing loss, and fatigue [20]. Although clinically well defined, the pathophysiology of muscle weakness in OI has not been studied yet. Similar to EDS those with OI have connective tissue defects; therefore it is likely to see hearing deficiency in patients with OI. Treatments for hearing loss in this population include amplification (hearing aids) and cochlear implants. Some patients may be candidate for stapedectomy and middle ear reconstruction.

Case study of an individual with EDS and bilateral hearing loss:

The reported case in the current paper is a 66 years old female and has had EDS since birth. The reported case in this article willingly consented to allow the authors to use her medical records for scientific and training purposes.

History: At 3 months of age, she reports that she turned blue and had an aneurysm. She indicated that she has been told that aneurysm is a sign of someone with EDS and a person with EDS tends to have fragile blood vessels that can cause an aneurysm. She also has had atypical seizures until the age of 40. These seizures have stopped once she was put

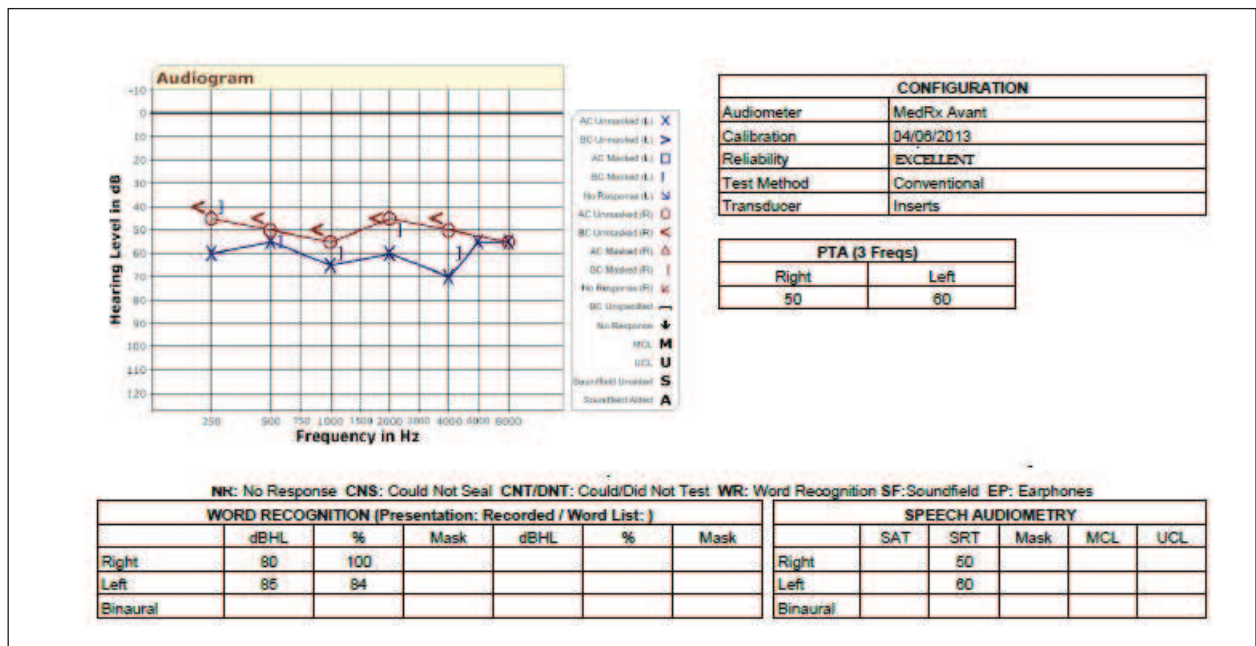


Figure 1. Audiologic data for the case report in this article (66 years old female). Hearing test data indicate asymmetric moderately severe sensorineural hearing loss which is slightly worse in the left ear. Note the negligible air-bone-gap in the left ear, secondary to the ventilation tube.

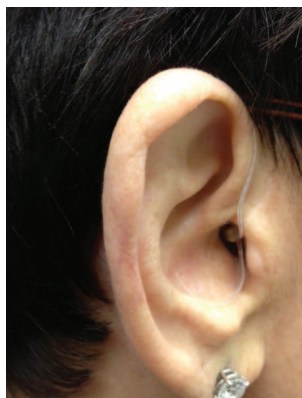

Figure 2. Receiver In The Ear (RITE) hearing aid used by this case on a daily basis.

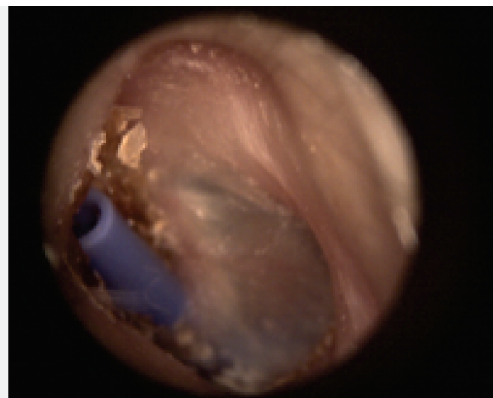
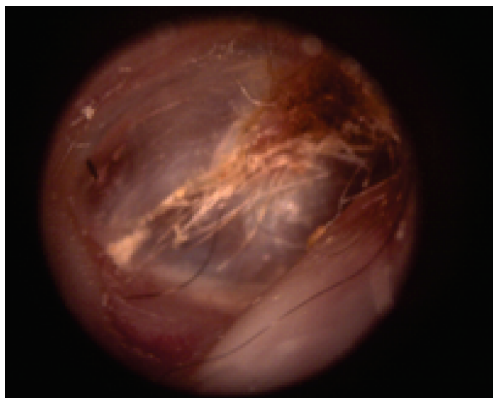


Figure 3. Videoscopic images of the right and left ears of the case with EDS. Note the presence of ventilation tube in the left ear.

on the correct dosage of medications. Currently she takes; Phenobarbital (38 mg once a day), Celestine (10 mg once a day), Wellbutrin (75 mg twice a day), and Valium (1 mg when needed, usually 2 or 3 times a day).

She also suffered from vision problems. In 2004 she received monovision eye surgery and three years later, in 2007, she had cataract surgery in both eyes. She also presents with a cyst under her retina in both eyes. Additionally she stated that she has had around 30 surgeries throughout her lifetime. Many of these surgeries are due to her having EDS. In 1992, she was in need of a hip replacement. Since then she has received hip surgery nine times. She also had surgery on both of her feet, the first being in 2011. This case suffers from flat feet, often a sign of someone who has EDS. Another complication of EDS is loose ligaments. Due to this, she has had the ligaments in her hands loosened and tightened. In 1999, she received gastric bypass surgery. Lastly, she indicated that she was in need of shoulder surgery due to her shoulder rotting away.

Ear and Hearing Status: She states that she began having hearing loss about 10 years ago. Currently, she has significant hearing loss in both ears (Figure 1). The audiometric data shows asymmetric moderately severe sensorineural hearing loss. Her hearing loss is worse in the left ear with a negligible air-bone-gap. She currently uses hearing aids since 2012 in both ears (Figure 2). She does not present with

tinnitus, but reports she sometimes becomes dizzy. She indicates that she has non-functioning Eustachian Tubes. Due to this, she has had ventilation tubes in her right ear from age 40-64. Her right ear had a T-tube which was removed in 2009 and currently there is no perforation on that side. This patient has received ventilation tube insertion in her left ear at age 59 which is currently in place and helps with the ventilation of her left ear middle ear cavity (Figure 3). There is no active drainage from either ear. She also reports that her mother and father both have had hearing problems. However, none has EDS.

Summary:

Team management of the otologic and audiological complications of individuals with EDS and hearing loss is very critical. It is important to address the communication needs of this population. In the current case study the otologic complications of this individual was controlled and has been monitored regularly. The patient's hearing loss has been compensated to a great degree with the use of amplification, auditory training and continuous aural rehabilitation and counseling. Close interaction and communication between the clinicians is the key in successful management of those with EDS and hearing loss.

Sažetak

Ehlers-Danlos sindrom (EDS) predstavlja genetički heterogenu grupu naslednih poremećaja vezivnog tkiva koji interferiraju sa funkcionisanjem kože, zglobova, ligamenata, krvnih sudova i raznih unutrašnjih organa i sistema. Sindrom tipično ispoljava izraženu elastičnost kože i širenje atrofičnih ožiljaka i modrica, kao i povećanu labavost i pokretljivost zglobova. Brojne komponente slušnog i vestibularnog sistema čoveka sadrže vezivno tkivo, npr. spoljašnje uvo, bubna opna, sinovijalna membrana zgloba srednjeg uva i deo unutrašnjeg uva. Zbog toga je vrlo verovatno da su kod osoba sa EDS zahvaćeni i slušni i vestibularni sistem.

REFERENCES:

1. Thomas D, Wright J, Soucek S, Shalom A. Ehlers-Danlos syndrome: aural manifestations and treatment. *Am J Otolaryngol.* 1996; 17: 432-3.
2. Byers PH & Murray ML. Ehlers-Danlos syndrome: A showcase of conditions that lead to understanding matrix biology. *Matrix Biol.* 2013 Aug 3 (In Press).
3. Tofts L, Elliott E, Munns C, Pacey V, Sillence D. The differential diagnosis of children with joint hypermobility: a review of the literature. *Pediatr Rheumatol Online J.* 2008; 6 (Suppl 1): P156.
4. Abdelmalek N F, Gerber T L, Menter A. Cardiocutaneous syndromes and associations. *J Am Acad Dermatol.* 2002;46, 2:161-83.
5. Castori M. Ehlers-Danlos Syndrome, Hypermobility Type: An Underdiagnosed Hereditary Connective Tissue Disorder with Mucocutaneous, Articular, and Systemic Manifestations. *ISRN Dermatol* 2012; 2012: 751-68.
6. Malfait F, & De Paepe A. Bleeding in the heritable connective tissue disorders: Mechanisms, diagnosis and treatment. *Blood Reviews.* 2009; 23: 191-7.
7. Premalatha S, Sarveswari KN, Lahiri K. Reverse-Namaskar: a new sign in Ehlers-Danlos syndrome: a family pedigree study of four generations. *Indian J Dermatol.* 2010; 55, 1: 86-91.
8. Callewaert B, Malfait F, Loeys B, De Paepe A. Ehlers-danlos syndromes and marfan syndrome. *Best Practice & Research Clin Rheumatol.* 2008; 22, 1: 165-89.
9. Baumann M, Giunta C, Krabichler B, Rüschenhoff F, Zoppi N, Colombi M et al. Mutations in FKBP14 Cause a Variant of Ehlers-Danlos Syndrome with Progressive Kyphoscoliosis, Myopathy, and Hearing Loss. *Am J Human Gen.* 2012; 90, 2: 201-16.
10. Hunter A, Morgan AW, Bird HA. Letters to the Editor. *British J Rheumatol.* 1998; 37, 7: 94-108.
11. Miyajima C, Ishimoto S, Yamasoba T. Otosclerosis associated with Ehlers-Danlos syndrome: report of a case. *Acta Oto-Laryngol.* 2007; 127: 157-9.
12. Mair I, Schroder K, & Johannessen T. Otosclerosis, Ehlers-Danlos syndrome and Melkersson-Rosenthal syndrome. *J Laryngol Otol.* 1974; 88, 11: 1061-66.
13. Mair I. Occasional stapes surgery - a Norwegian experience. *J Laryngol Otol.* 1989; 103: 259-62.
14. Al-Owain M, Al-Dosari MS, Sunker A, Shuaib T, Alkuraya FS. Identification of a novel ZNF469 mutation in a large family with Ehlers-Danlos phenotype. *Gene.* 2012; Dec15, 511, 2: 447-50.
15. Loeys B, Dietz H, Dietz A, Callewaert B, DeBacker J, Devereux R, DePaepe A. The revised Ghent nosology for the Marfan syndrome. *J Med Genet.* 2010; 47, 7: 476-85.
16. Al-Hussain H, Zeisberger S.M, Huber PR, Giunta C, Steinmann B. Brittle cornea syndrome and its delineation from the kyphoscoliotic type of Ehlers-Danlos syndrome (EDS VI): report on 23 patients and review of the literature. *Am J Med. Genet.* 2004; 124A: 28-34.
17. Yeowell HN, Steinmann B. Ehlers-Danlos syndrome, kyphoscoliotic form. In: Pagon RA, Bird TD, Dolan CR, Stephens K, Adam MP. (Eds.), *Source: GeneReviews™* ŠInternetĀ. Seattle (WA): University of Washington, Seattle, 1993.
18. Christensen AE, Knappskog PM, Midtbø M, Gjesdal CG, Mengel-From J, Morling N et al. Brittle cornea syndrome associated with a missense mutation in the zinc-finger 469 gene. *Invest Ophthalmol Vis Sci.* 2010; 51, 1: 47-52.
19. Cabral WA, Makareeva E, Letocha AD, Scribanu N, Fertala A, Steplewski A et al. Y-position cysteine substitution in type I collagen (alpha1(I) R888C/p.R1066C) is associated with osteogenesis imperfecta/Ehlers-Danlos syndrome phenotype. *Hum Mutat.* 2007; Apr;28, 4: 396-405.
20. Pillion JP, Vernick D, Shapiro J. Hearing loss in osteogenesis imperfecta: characteristics and treatment considerations. *Genet Res Int.* 2011; 983942. Published online 2011 December 14.

■ The invited paper was received and accepted on 07.11.2013.